

Single inguinal node metastasis of stage I testicular seminoma shown by scrotal scintigraphy, 6 months following radical orchiectomy

Athanasios Bantis¹ MD, MSc, PhD,
 Petros Sountoulides¹ MD,
 Christos Kalaitzis¹ MD,
 Boussios Nikolaos² MD,
 Stilianos Giannakopoulos¹ MD,
 Athanasios Zissimopoulos² MD

1. Department of Urology,
 2. Department of Nuclear
 Medicine, University Hospital of
 Alexandroupolis, Dragana 68100,
 Alexandroupolis, Greece

Keywords: Inguinal lymph nodes
 – Radionuclide scintigraphy
 – Testicular seminoma

Correspondence address:

Athanasios Bantis MD, MSc, PhD,
 Department of Urology,
 University Hospital of Alex-
 androupolis, Dragana 68100,
 Alexandroupolis, Greece
 Email : bantis68@otenet.gr

Received:

16 January 2012

Accepted revised:

30 March 2012

Abstract

Lymphatic drainage of the testes is known to follow a predictable pathway that usually involves the retroperitoneal, paraaortic, paracaval and interaortocaval nodal chains. Herein *we report the case of* a 41 years old man with a stage I testicular seminoma, with an unexpected inguinal lymph node metastasis. During his routine follow-up visit, 6 months after radical orchiectomy, a spherical mass in the right inguinal region was palpated. Thoraco-abdominal CT did not reveal any evidence of retroperitoneal enlarged lymph nodes or distant metastases, but showed a 2cm right inguinal mass. Scrotal scintigraphy with technetium-99m pertechnetate was performed in order to evaluate the local vascularity of the right inguinal area. The angiographic phase (0-1min) and the blood pool images at 15, 30, 45 and 60min revealed high uptake in the right inguinal region, suggesting a hyperemic mass suspicious for tumor recurrence. The excised mass was found to be an enlarged lymph node infiltrated with seminoma. The patient received adjuvant radiotherapy to which he showed a complete response and has been disease free at 2 years follow-up. *In conclusion*, in the case presented scrotal scintigraphy showed a hyperemic mass at the right inguinal region that proved to be the sentinel node of a stage I testicular seminoma and was treated accordingly.

Hell J Nucl Med 2012; 15(2): 150-152

Epub ahead of print: 27 June 2012

Abstracted on line: 27 June 2012

Introduction

The pattern of lymphatic drainage from the testes is known to involve the retroperitoneal lymph node chain from the level of the iliac vessels up to the level of the renal hilum. Primary involvement of the inguinal nodes from testicular tumors is rare. The main reason proposed for this rarity is a history of previous inguinal or scrotal surgery that may have altered the pattern of lymphatic drainage. In this study we present a rare case of a single metastasis to the inguinal lymph nodes 6 months following radical orchiectomy for stage I testicular seminoma. We will also review the literature and discuss controversial issues such as the optimal adjuvant treatment for patients with stage I seminoma.

Case report

A 41 years old male patient presented with a palpable painless scrotal mass. There was no history of cryptorchidism, trauma or surgery in the inguinal or scrotal area and his contralateral testicle was normal. His human chorionic gonadotropin (HCG) level and other serum tumor markers, including lactate dehydrogenase (LDH) were within normal limits. Ultrasonographic features of the mass were consistent with seminoma. Preoperative abdominal computer tomography (CT) was negative for enlarged lymph nodes or distant metastases and the patient underwent an uneventful right inguinal orchiectomy. Pathology revealed a, 2cm in diameter, pure seminoma without involvement of the tunica albuginea or rete testis.

The case was considered as stage I seminoma, and the patient was offered prophylactic radiotherapy or surveillance. The patient opted for surveillance. In the 3months postoperative office visit, serum tumor markers remained within normal levels and physical examination was normal. At 6 months follow-up, clinical examination revealed the presence of a painless, mobile, spherical mass in the right inguinal region. Thoraco-abdominal CT did not reveal any evidence of retroperitoneal enlarged lymph nodes or distant metastases, but showed a 2cm right inguinal mass. In order to evaluate the vascularity of the mass,

scintigraphy with free pertechnetate was performed using the protocol of scrotal scintigraphy. The patient was positioned supine under the single-head gamma-camera (GE Millennium MPS, Milwaukee USA) with the penis taped to the anterior abdominal wall. His legs were abducted to diminish overlap of soft tissue thigh activity and 370MBq technetium-99m pertechnetate was injected intravenously. Thyroidal uptake was blocked by the administration of potassium perchlorate (6mg/kg).

In the angiographic phase (flow images at 0-1min) the iliac arteries were seen simultaneously and symmetric with a high focal uptake in the right inguinal region, suggesting a hyper vascular mass (Fig. 1). Blood pool images at 15, 30, 45, 60 and 120min (Fig. 2) were performed. Vascular activity was present and the penis appeared as a hot linear collection of activity, located above the scrotum. First hour blood pool images showed elevated perfusion in the right inguinal area, a finding hardly seen 2h after the injection of the radiopharmaceutical. This local hyperemia was considered consistent with tumor recurrence. The hyperemic mass was surgically excised (Fig. 3) and pathology revealed a lymph node infiltrated by pure seminoma. The patient was scheduled to receive adjuvant radiation treatment and was disease free after 2 years.

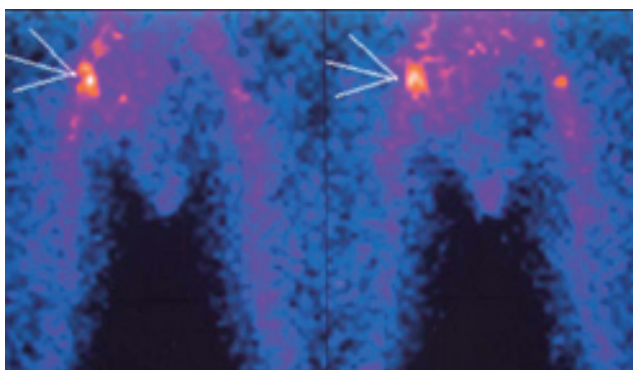


Figure 1. Dynamic radionuclide scintigraphy (angiographic phase: 0-1min). Images at the 15th and 16th sec after injection of the radiopharmaceutical, showing increased focal uptake at the right inguinal region.

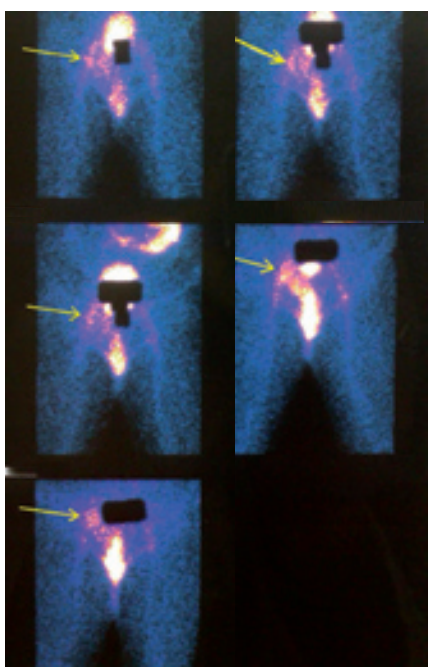


Figure 2. Blood pool images at 15min, 30min, 45min, 60min and 120min showing high perfusion at the right inguinal region. The activity in the region faints with time. Radioactivity is also seen in the bladder, iliac arteries, penis and intestine.

Discussion

Stage I seminoma is the most commonly reported stage of seminomatous testicular cancer, comprising up to 80% of seminomas and 40% of all testicular cancers [1].

Orchiectomy followed by surveillance provides cure for the majority of patients with stage I seminoma. Current treatment alternatives to surveillance include radiotherapy (RT) or chemotherapy with carboplatin [2].

Radiotherapy may be recommended even though there are no proven lymph node metastases, because in about 1 of 5 patients cancerous cells may have metastasized, but cannot be detected by imaging techniques. By applying about 15 treatments of RT to the retroperitoneum area, the chance of recurrence becomes less than 5%. Additional RT to the pelvis does not reduce the overall risk of recurrence. Using two doses of carboplatin after orchiectomy, the risk of recurrence can be reduced from 18% to about 2% and to about 5% with a single dose of carboplatin [3]. The disadvantage of combining RT and chemotherapy for clinical stage I seminoma is that more than 80% of patients receive treatment that they do not need [4].

Recently, a correlation between RT and late secondary cancers has been shown and as a result surveillance has become the most frequent treatment of choice [5, 6], although patients not always comply with the relatively strict follow-up scheme. A recent report showed that 21% of seminoma patients on surveillance, after a median time of 5.5 years did not further comply with the follow-up scheme [4, 7].

The incidence of inguinal lymph node metastases in patients with initial stage I testicular seminoma is very rare [8]. In these cases there is often a history of scrotal or inguinal surgery.

In the case presented, CT revealed the enlarged inguinal lymph node. Because of the rarity of a solitary inguinal metastasis (<0.5%) from testicular cancer [8], we performed dynamic and static scintigraphy with technetium-99m pertechnetate, to evaluate the vascularity of the palpable mass. We found increased blood flow, suggesting a hypervascular mass that could be attributed to inflammatory or neoplastic process. Clinical and laboratory tests did not support inflammation and the patient's history advocated tumor recurrence. This palpable mass was an infiltrated lymph node and after 2 years follow-up was considered the sentinel lymph node (SLN).

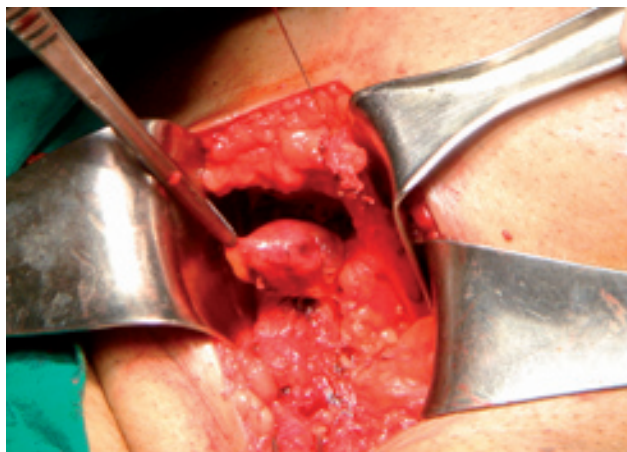


Figure 3. Exploratory laparotomy. Detailed surgical preparation demonstrates an enlarged lymph node

The SLN is almost always located at the ventral or lateral side of the vena cava or at the bifurcation of the aorta, by the renal vein or the obturator lymph node area [9]. Rarely, an additional SLN may be found adjacent to the testicular vessels [10].

In conclusion, this case presents a rare inguinal lymph node metastasis as SLN, 6 months after radical orchiectomy for testicular seminoma possibly due to intraoperative handling of the testis. To our knowledge this is the first report of a single lymph node metastasis from testicular seminoma imaged with scrotal scintigraphy.

The authors declare that they have no conflicts of interest.

Bibliography

1. Cooper DE, L'Esperance JO, Christman MS, Auge BK. Testis cancer: a 20-year epidemiological review of the experience at a regional military medical facility. *J Urol* 2008; 180: 577-81.
2. Oliver RT, Mead GM, Rustin GJ et al. Randomized trial of carboplatin versus radiotherapy for stage I seminoma: mature results on relapse and contralateral testis cancer rates in MRC TE19/EORTC 30982 study (ISRCTN27163214). *J Clin Oncol* 2011; 29(8): 957-62.

3. Gilligan T. Change management of clinical low stage testicular cancer. *The Scient World J* 2005; 5: 852-67.
4. Alomary I, Samant R, Gallant V. Treatment of stage I seminoma: a 15-year review. *Urol Oncol* 2006; 24: 180-3.
5. Travis LB, Fossa SD, Schonfeld SJ et al. Second cancers among 40,576 testicular cancer patients: focus on long-term survivors. *J Natl Cancer Inst* 2005; 97: 1354-65.
6. Van den Belt-Dusebout AW, de Wit R, Gietema JA et al. Treatment-specific risks of second malignancies and cardiovascular disease in 5-year survivors of testicular cancer. *J Clin Oncol* 2007; 25: 4370-8.
7. Choo R, Thomas G, Woo T et al. Long-term outcome of postorchiectomy surveillance for Stage I testicular seminoma. *Intern J Radiat Oncol, Biology Physics* 2005; 61: 736-40.
8. Daugaard G, Karas V, Sommer P. Inguinal metastases from testicular cancer. *BJU Int* 2006; 97: 724-6.
9. Bantis A, Sountoulides P, Kalaitzis C et al. Positive lymphoscintigraphy (ILS) and negative computed tomography for metastatic penile cancer. *Hell J Nucl Med* 2011; 14: 309-10.
10. Brouwer OR, Valdis Olmos RA, Vermeeren L et al. SPECT/CT and a portable gamma-camera for image-guided laparoscopic sentinel node biopsy in testicular cancer. *J Nucl Med* 2011; 52: 551-4.



Utagawa Yoshitsuya (Japanese), 1892: Protection from measles epidemic. Xylography.