

Conservative management of penile trauma may be complicated by abscess formation

Athanasios Bantis,¹ Petros Sountoulides,¹ Christos Kalaitzis,¹ Savas Deftereos²

Departments of ¹Urology and ²Radiology, University Hospital of Alexandroupolis, Alexandroupolis, Greece

Abstract

Blunt penile trauma during sexual activity, although highly underreported due to the associated patient embarrassment, constitutes a real urological emergency requiring immediate attention and possibly early surgical intervention. We report a case of a 58-year old man who presented with penile pain following excessive masturbation. Although there were no clinical signs of penile deformity or hematoma, magnetic resonance imaging revealed the presence of a rupture in the tunica albuginea. The patient opted for non-surgical management and his recovery period was complicated by the formation of an abscess at the site of the albugineal tear thus prolonging his hospital stay. The abscess was surgically drained and the patient reports to have normal erections at 3-month follow up.

Introduction

Although highly underreported due to patient embarrassment and discomfort penile fracture is a real urological emergency that warrants urgent surgical management and can potentially lead to long-term complications like erectile dysfunction, pain on erection, penile curvature and palpable plaque. Penile fracture is defined as rupture of the tunica albuginea of corpus cavernosum due to blunt trauma to the erect penis.¹

The first report of this condition is credited to an Arab physician, Abul Kasem, in Cordova over 1000 years ago. Most documented cases involve rupture of one or both of the corpora cavernosa, with a reported incidence of associated urethral injury ranging from 3% to 38%.² We report a rare case of penile trauma causing rupture of the tunica albuginea during aggressive masturbation which, under conservative treatment, resulted in abscess formation requiring delayed surgical intervention.

Case Report

A 58-year old male presented to the emergency department complaining for pain at the left side of the base of his penis 4 h after excessive forceful masturbation. His medical and surgical history was unremarkable and he was under no medications whatsoever. At physical examination there were no signs of penile deformation, or expanding hematoma although the formation of a small hematoma was noticed at the base of the penis (Figure 1). Abdominal examination was unremarkable, although the bladder was distended and palpable. The scrotum was painful at palpation, but the testicles were normal. The patient was able to void without hematuria and there were no evidence of urethral injury on retrograde urethrogram. The patient was consulted that this was a case of trauma causing rupture of the cavernous body that should be best managed surgically. However he did not consent for surgical exploration of the trauma and for this reason conservative management with broad spectrum antibiotics and low molecular weight heparin was administered. As penile ultrasonography was not available for technical reasons, the next day a magnetic resonance imaging (MRI) of the penis was performed in order to further investigate the extent of the traumatic lesion. Axial T1-weighted MRI showed a small tear in the tunica albuginea and hematoma in the left side of the base of the penis. (Figure 2). After 3 days of conservative treatment the area of hematoma collection became erythematous and painful giving the impression of an abscess formation while the white blood cell count increased from 9000 to 21,000. The following day the abscess drained spontaneously to the skin, the patient was relieved from pain and the blood count returned to normal (Figure 3). The pus culture from the abscess revealed *Staphylococcus aureus*. The patient was subjected to drainage and surgical debridement of the abscess.

The patient was discharged after 12 days of hospitalization with per oral somministration antibiotics administered for additional 10 days. With regard to his sexual ability, 3 months after the incidence he reported *normal erections* although he was not willing to complete the International Index of Erectile Function (IIEF) questionnaire or undergo a penile Doppler examination. The patient did not report any other mid- or long-term complications.

Discussion

Blunt trauma to the erect penis usually during sexual activity is termed penile fracture. A

Correspondence: Petros Sountoulides, 15-17 Agiou Evgeniou street, 55133, Thessaloniki, Greece.
E-mail: sountp@hotmail.com

Key words: penile trauma, penile abscess, masturbation, magnetic resonance imaging.

Conflicts of interest: the authors declare no potential conflicts of interest.

Contributions: the manuscript has been read and approved by all authors and the requirements for authorship have been met.

Received for publication: 7 May 2014.

Revision received: 2 September 2014.

Accepted for publication: 10 September 2014.

This work is licensed under a Creative Commons Attribution NonCommercial 3.0 License (CC BY-NC 3.0).

©Copyright A. Bantis et al., 2014

Licensee PAGEPress, Italy

Clinics and Practice 2014; 4:648

doi:10.4081/cp.2014.648

common mechanism of injury is when the penis during intercourse hits against the pubic bone or perineal area although masturbation can be the cause in up to 60% of cases.³ Penile fracture is caused by rupture of the cavernous tunica albuginea and may be associated with subcutaneous hematoma, and lesions of the corpus spongiosum or urethral injury in 10-22% of cases.^{2,4}

The tunica albuginea is a structure of great tensile strength that is able to withstand rupture at pressures up to 1500 mmHg. The tunica albuginea thins markedly in the erect state (from approximately 2 mm in the flaccid state to 0.25-0.5 mm) which when combined with abnormal bending leads to excessive intracavernosal pressure and most often a transverse laceration of the proximal shaft.⁵

Patient history and clinical examination were highly sensitive and sufficiently accurate in predicting a cavernosal tear. The basic differential diagnosis is from a tear in the dorsal vein of the penis leading to subcutaneous hematoma, a condition that should be managed conservatively.⁶ Still, the distinction between the two situations is not difficult as penile fracture is classically associated unphysiological bending of the tumescent penis followed by rapid post-traumatic detumescence.¹

Imaging studies may be used to confirm the diagnosis is not so straightforward cases but in general they do not influence the treatment decision. Ultrasonography is highly specific but not very sensitive for detecting a cavernosal tear.⁷

Magnetic resonance imaging has also been advocated for the investigation of unclear cases where laceration of the tunica albuginea is not evident at physical examination. MRI undoubtedly gives high-quality images and is more accurate than ultrasonography in the detection of small cavernosal tears.⁸

In cases of penile fracture immediate surgical correction of the defect has been associated with shorter duration of hospital stay, higher levels of patient satisfaction, and improved outcomes including reduced incidence of erectile dysfunction and penile curvature.^{3,4}

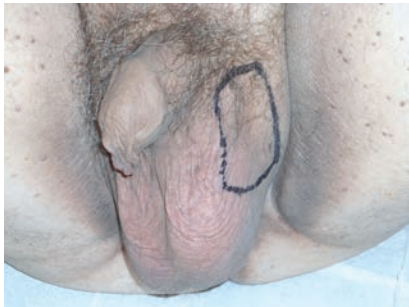

Figure 1. Clinical examination of the patient 5 h after the incident. Palpable mass at the left side of the base of the penis (area in black marker).

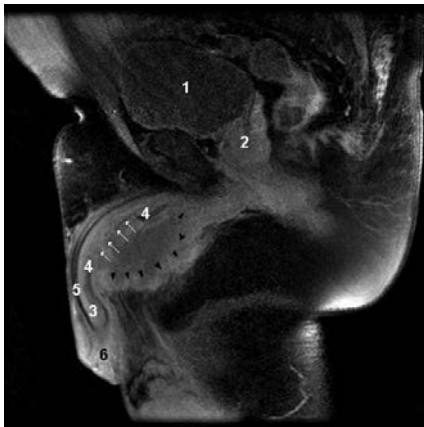


Figure 2. Axial T1-weighted magnetic resonance image showing the rupture of the tunica albuginea (white arrows) and expanding hematoma on the left base of the penis (black arrows). 1=bladder, 2=prostate, 3=corpus cavernosum, 4=tunica albuginea, 5=urethra, 6=glans penis.

Conservative treatment of penile fracture is not recommended as it is associated with a high incidence of penile deformities, angulations and fibrosis leading to severe long term complications like erectile dysfunction.¹ Our patient was initially managed conservatively but the evolution of the hematoma to abscess and finally the spontaneously rupture was not satisfactory. The patient had relief of severe pain which could not have occurred if gave the initial consent for immediate surgery intervention. Abscess formation in the penis has been described in association with penile prosthesis, priapism, cavernosography, intracavernosal injection therapy, sexually transmitted diseases and trauma. To our knowledge this is the 3rd report of abscess formation following penile fracture. In the first case penile abscess was the result of intracavernosal drug injection for erectile dysfunction in a diabetic patient,⁹ while in the second case the patient had suffered a blunt penile trauma during sexual intercourse 3 weeks ago.¹⁰ The common element in all cases was that penile fractures were either neglected or managed conservatively, as in our case.

Conclusions

Excessive forceful masturbation can cause rupture of the tunica albuginea in rare cases. Although the signs and symptoms may be more subtle compared to penile fracture during intercourse the presence of a penile hematoma warrants immediate attention and imaging studies to confirm or exclude rupture of the tunica albuginea. The patients should be

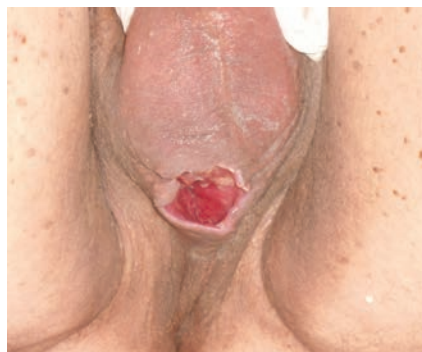

Figure 3. The ruptured abscess cavity before surgical debridement.

advised that surgical management should be considered even in cases of minor lacerations in order to spare the risk of penile abscess formation with delayed surgical intervention and additional sequelae.

References

1. Lynch TH, Martínez-Piñero L, Plas E, et al. EAU guidelines on urological trauma. *Eur Urol* 2005;47:1-15.
2. Zargooshi J. Penile fracture in Kermanshah, Iran: report of 172 cases. *J Urol* 2000;164:364-6.
3. El Atat R, Sfaxi M, Benslama MR, et al. Fracture of the penis: management and long-term results of surgical treatment. Experience in 300 cases. *J Trauma* 2008;64:121-5.
4. Lee SH, Bak CW, Choi MH, et al. Trauma to male genital organs: a 10-year review of 156 patients, including 118 treated by surgery. *BJU Int* 2008;101:211-5.
5. Bitsch M, Kromann-Andersen B, Schou J, Sjøntoft E. The elasticity and the tensile strength of the tunica albuginea of the corpora cavernosa. *J Urol* 1990;143:642-5.
6. Faydaci G, Ozgul A, Kuyumcuoglu U, et al. Dorsal vein rupture after practice of taqaandan, necrotising cavernositis, penile reconstruction, urethroplasty and penile prosthesis implantation. *Andrologia* 2012;44:851-5.
7. Agarwal MM, Singh SK, Sharma DK, et al. Fracture of the penis: a radiological or clinical diagnosis? A case series and literature review. *Can J Urol* 2009;16:4568-75.
8. Fedel M, Venz S, Andreessen R, et al. The value of magnetic resonance imaging in the diagnosis of suspected penile fracture with atypical clinical findings. *J Urol* 1996;155:1924-7.
9. Song W, Ko KJ, Shin SJ, Ryu DS. Penile abscess secondary to neglected penile fracture after intracavernosal vasoactive drug injection. *World J Mens Health* 2012;30:189-91.
10. Al-Reshaid RA, Madbouly K, Al-Jasser A. Penile abscess and necrotizing fasciitis secondary to neglected false penile fracture. *Urol Ann* 2010;2:86-8.